

Laparoscopic Bladder-Sparing Approach in Patients with Prostatic Rhabdomyosarcoma: A Case Series of Two Pediatric Patients

Ender Ozden¹, Mehmet Necmettin Mercimek^{2*}, Saban Sarikaya¹

Traditionally, the standard treatment of bladder-prostate rhabdomyosarcoma (BP-RMS) is total cystoprostatectomy and urinary diversion. However, current multimodal treatment approaches emphasize the importance of bladder-sparing surgery. In this case series, we aimed to indicate the results of the laparoscopic bladder-sparing approach of two pediatric patients with BP-RMS. They were admitted to the emergency department due to acute urinary retention (AUR). The tumors located in the prostate causing AUR were detected by Magnetic resonance imaging (MRI) and the pathological diagnosis was confirmed by biopsy. The patients were managed in a prosperous manner by implementing laparoscopic surgery with the cause of detection of a significant decrease in the size as well as the enhancement pattern of the tumors following neoadjuvant chemotherapy. No urinary incontinence, tumor recurrence or metastasis was observed at 36 and 28 months follow-up in case 1 and case 2, respectively. Laparoscopic bladder-sparing approaches may have an advantage in patients with BP-RMS to decrease morbidity and mortality related to radical surgery. To our knowledge, these are the first cases of laparoscopic bladder-sparing approach in the treatment of pediatric prostate-derived embryonal RMS (PDERMS).

Keywords: laparoscopy; radical prostatectomy; partial prostatectomy; rhabdomyosarcoma

INTRODUCTION

Rhabdomyosarcoma (RMS) comprises the most frequent soft tissue sarcoma in pediatrics. The genitourinary system is the second most frequent location for involvement. Thereabouts 75% of bladder-prostate rhabdomyosarcoma (BP-RMS) consists of male predominance and most cases take place in children aged 5 years and younger.^(1,2) At the time of diagnosis a vast majority of the BP-RMSs often invade adjacent organs and vascular structures therefore, it may not be possible to achieve a complete tumor resection at surgery.⁽³⁾ Recent clinical trials recommend primary chemotherapy as the initial treatment modality for the management

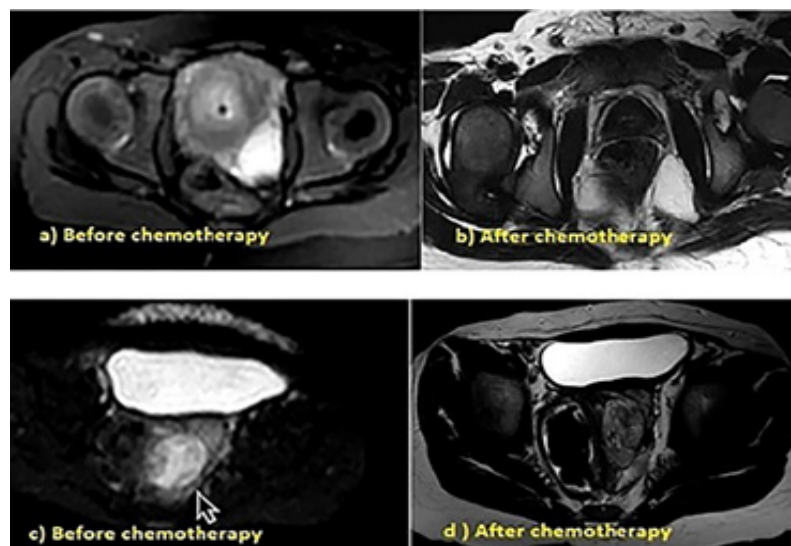


Figure 1. MR images of case 1 before (a) and after chemotherapy (b), MR images of case 2 before (c) and after chemotherapy (d)

¹Department of Urology, Faculty of Medicine, Ondokuz Mayıs University, Atakum, Samsun 55210, Turkey.

²Department of Urology, Samsun Liv Hospital, İlkadım, Samsun 55020, Turkey.

*Correspondence: Department of Urology, Samsun Liv Hospital, İlkadım, Samsun 55020, Turkey.

Tel: +90 543 534 39 64, Fax: +90 362 999 80 80, E-mail: m.n.mercimek@hotmail.com.

Received March 2019 & Accepted May 2019

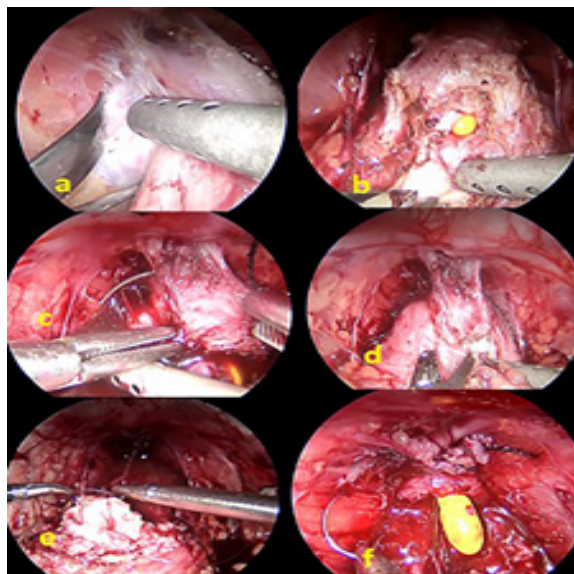


Figure 2. 3 mm of laparoscopic instruments were used during the operation. Per-operative images of case 1, **a:** dissection of the endo-pelvic fascia on the left side by cold scissors, **b:** bladder neck dissection, **c:** control of deep dorsal vein complex, **d:** apical dissection of the prostate, **e and f:** Urethrovesical anastomosis with Van Velthoven technique.

of BP-RMSs. Partial or radical surgery, as well as radiotherapy, may be one of the multimodal treatment options according to the chemotherapy response of the tumor. However, some authors advocate radical extirpative surgery to prevent local recurrence which is a considerable cause of cancer-related morbidity and mortality.^(3,4)

Current treatment recommendations consider bladder-sparing approaches to decrease morbidity and mortality related to radical cystoprostatectomy in pediatric

patients.⁽⁴⁾

Herein, we aimed to report laparoscopic bladder-sparing surgery in two pediatric cases with prostate RMS. To our knowledge, there is no report that shows laparoscopic approach to perform bladder-sparing surgery in this regard.

CASE PRESENTATION

After obtaining ethical approval from the Ethics Committee of Ondokuz Mayıs University (OMU KAEEK 2019/77), the written informed consents were obtained from the parents of the patients prior to their database inclusion.

Case 1: A 2-year-old male patient admitted for urinary retention was found to have papillary lesions on the prostatic urethra, had transurethral resection (TUR) biopsy which revealed pediatric prostate-derived embryonal RMS (PDERMS). Globe vesicale was detected on physical examination and a urethral catheter was inserted. Complete blood count, blood biochemical tests, urine analysis, and urine culture were normal before the biopsy. Magnetic resonance imaging (MRI) showed a diffusely enlarged prostatic mass lesion, 30x21mm in size (**Figure1: a**), and the tumor was also found out to invade the seminal vesicle and the bladder neck on the left side. After receiving 4 cycles of chemotherapy, control MRI showed a decrease in prostatic size and accompanying lesions (**Figure1: b**). Laparoscopic radical prostatectomy (LRP) was performed (**Figure 2**). No urinary incontinence, tumor recurrence or metastasis was observed at 36 months follow-up. Moreover, it is also stated by his parents that morning erection exists on the last visit.

Case 2: A 2-year-old male patient admitted for fecal and urinary retention was found to have 5 x 5 cm lesion originated from prostate which compressed the left edge of the rectum (**Figure1:c**). On initial physical examination, abdominal distention and globe vesicale were detected. Tru-cut biopsy performed and

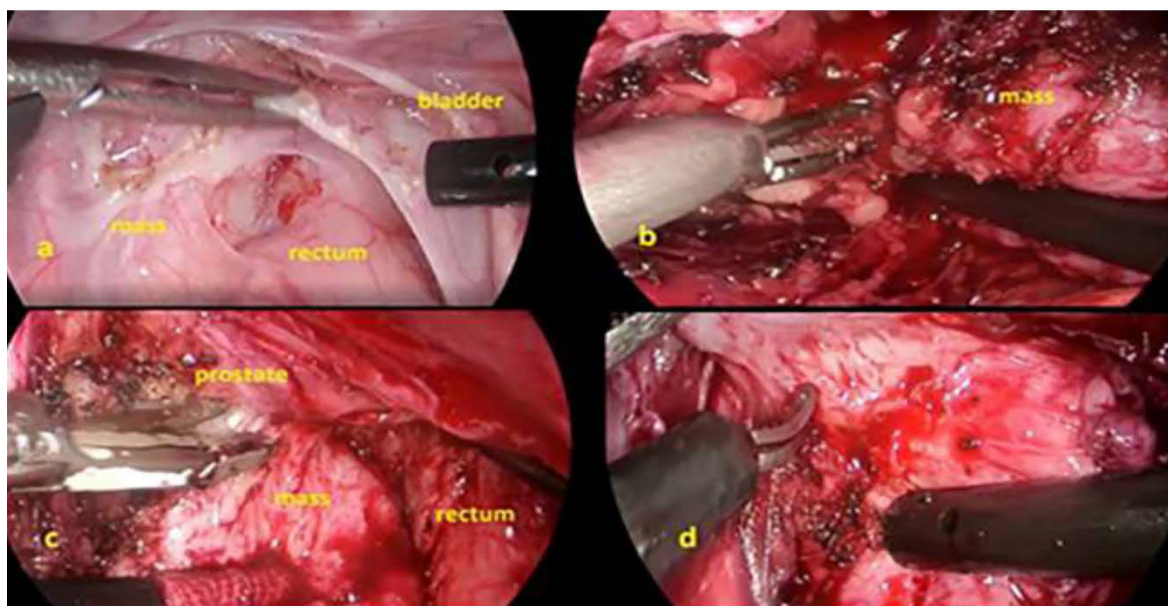


Figure 3. Per-operative images of case 2, **a:** relationship of the mass with bladder and rectum; transperitoneal appearance, **b:** dissection of the cranial side of the mass, **c:** dissection from the posterolateral side of the prostate, **d:** dissection of the caudal side of the mass

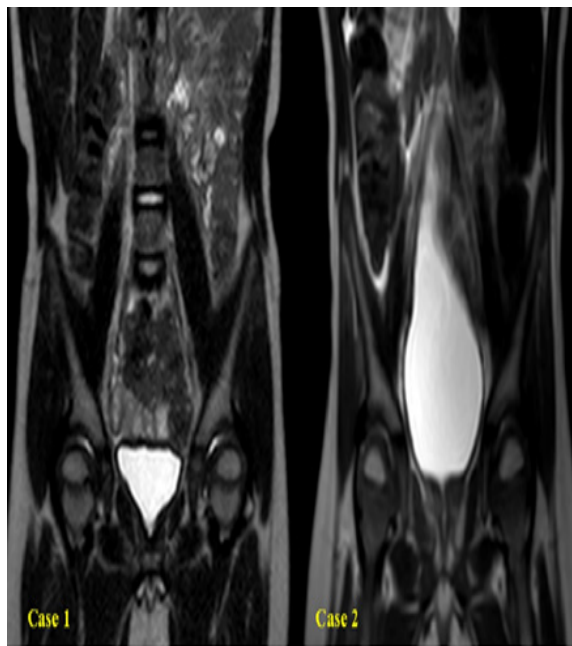


Figure 4. No tumor recurrence or metastasis on follow-up

reported as PDERMS. After receiving 4 cycles of CE-VAIE chemotherapy MRI showed a decrease in mass size (**Figure 1: d**). Laparoscopic partial prostatectomy (LPP) was performed (**Figure 2**). No urinary incontinence, tumor recurrence or metastasis was observed at 28 months follow-up. Moreover, it is also stated by his parents that morning erection exists on the last visit. In both of patients, final pathology revealed no tumor in the prostate with fibrosis and hyalinization on some parts secondary to regressed tumor. If local recurrence had occurred in follow-up, radiotherapy or radical surgery would have been scheduled from the oncological point of view. However, there was no need for such an approach in their follow-up. Thus, only MRI was performed to the patients with an interval of 3 months on follow-up according to the decision of the pediatric oncology and urology boards.

DISCUSSION

Radical cystectomy and radical prostatectomy are considered to be more mutilating surgeries because of the high morbidity in children. Because it was reported the vast majority of patients have challenges in maintaining urinary continence after radical surgeries. In addition, it was stated that the difficulties of applying surgery such as radical prostatectomy in children and the need for pubectomy for surgical exposure.⁽⁵⁾

A result of years of efforts of many international organizations such as Children's Oncology Group and International Society for Pediatric Oncology, the overall survival rate associated with RMS has increased from 25% to 75%.⁽⁴⁾ Since pediatric BP-RMSs constitute a heterogeneous group of patients, there is still no clear consensus about the limitations of surgical treatment in the literature. Many authors suggest a bladder-sparing approach in the case of chemotherapy-sensitive disease, while some advocate radical surgery to prevent local relapse. If the bladder-sparing surgery fails in the eradi-

cation of the tumor, delayed cystoprostatectomy can be performed and survival results are satisfactory.^(3,6)

To date, there is no information about laparoscopic radical and partial prostatectomy for the treatment of pediatric BP-RMS. In these index 2 cases, due to the achievement of partial response with chemotherapy (> 50% reduction in tumor volume, a significant reduction in contrast enhancement radiologically), conservative approaches to bladder preservation were preferred. Complete removal of the residual mass and the preservation of lower urinary tract functions and erectile functions have led to the idea that significant gains in quality of life may be achieved.

In the treatment of prostatic RMS, bladder-sparing LRP and LPP may be used as part of the multimodal treatment approach. The advantages of the laparoscopic method can be counted as no need for pubectomy compared to open prostatectomy, and that the vesicourethral anastomosis is performed under better vision.

The lack of randomized controlled trials and meta-analysis for the laparoscopic treatment of pediatric patients with BP-RMS causes uncertainties in terms of efficacy and reliability of the laparoscopic method. Nonetheless, in conclusion, this case series showed that laparoscopic bladder-sparing approach can be considered as an alternative treatment option in tumors in which local control is achieved by chemotherapy.

REFERENCES

1. Kieran K, Shnorhavorian M. Current standards of care in bladder and prostate rhabdomyosarcoma. *Urol Oncol*. 2016;34:93-102.
2. Saltzman AF, Cost NG. Current Treatment of Pediatric Bladder and Prostate Rhabdomyosarcoma. *Curr Urol Rep*. 2018;19:11.
3. Hishiki T, Saito T, Mitsunaga T, et al. Optimal surgical treatment and urological outcomes in boys with pelvic and urogenital rhabdomyosarcomas and soft tissue sarcomas. *Pediatr Surg Int*. 2013;29:1077-82.
4. Angelini L, Bisogno G, Esposito C, Castagnetti M. Appraisal of the role of radical prostatectomy for rhabdomyosarcoma in children: oncological and urological outcome. *Ther Adv Urol*. 2018;10:189-96.
5. Jenney M, Oberlin O, Audry G, et al. Conservative approach in localised rhabdomyosarcoma of the bladder and prostate: results from International Society of Paediatric Oncology (SIOP) studies: malignant mesenchymal tumour (MMT) 84, 89 and 95. *Pediatr Blood Cancer*. 2014;61:217-22.
6. Komasa L, Golebiewski A, Anzelewicz S, Czauderna P. A review on surgical techniques and organ sparing procedures in bladder/prostate rhabdomyosarcoma. *Eur J Pediatr Surg*. 2014;24:467-73.