Immediate Intravesical Instillation of Mitomycin C after Transurethral Resection of Bladder Tumor in Patients with Low-Risk Superficial Transitional Cell Carcinoma of Bladder

Mohammad Reza Barghi,[1] Mohammad Reza Rahmani,[1] Seyed Mohammad Mehdi Hosseini Moghaddam,[2] Mehrnoosh Jahanbin[2]

Introduction: The aim of this study was to evaluate the effect of immediate intravesical instillation of mitomycin C after transurethral resection of bladder tumor (TURBT) in patients with low-risk superficial transitional cell carcinoma (TCC).

Materials and Methods: A total of 43 patients with low-risk superficial bladder cancer were randomly assigned into two groups after the surgery; 22 patients in group 1 were treated by immediate instillation of mitomycin C after TURBT, and 21 patients in group 2 received placebo. The two groups were compared using urine cytology and cystoscopy during the 24 postoperative months.

Results: Recurrence within the first 3 months was reported in none of the patients in group 1 and 5 in group 2 ($P = .02$). Of these, 4 had recurrence of tumor in the primary site. At 12 and 24 months, there were 1 patient (4.5%) in group 1 and 8 (38.1%) in group 2 with recurrence ($P = .007$). We had no patients with multifocal recurrence in group 1, but 3 (14.2%) in group 2. Nine-month tumor-free survival rate was 95% in group 1. Three-, 6-, 9-, and 12-month tumor-free survival rates in group 2 were 76%, 71%, 66%, and 62%, respectively ($P = .007$). None of the patients in group 1 and 3 in group 2 (14.3%) experienced some degrees of tumor progression ($P = .06$).

Conclusions: Immediate instillation of mitomycin C after TURBT seems to be effective in the recurrence reduction and increase of recurrence-free interval at least in short term.

Keywords: bladder cancer, transitional cell carcinoma, drug instillation, mitomycin, transurethral resection

Urol J (Tehran). 2006;4:220-4.
www.uj.unrc.ir

1Department of Urology, Shohada-e-Tajrish Hospital, Shaheed Beheshti University of Medical Sciences, Tehran, Iran
2Urology and Nephrology Research Center, Shaheed Beheshti University of Medical Sciences, Tehran, Iran

Corresponding Author:
Syed Mohammad Mehdi Hosseini Moghaddam, MD
Urology and Nephrology Research Center
No 44, 9th Boustan, Pasdaran Ave, Tehran 1666679951, Iran
Tel: +98 21 22567222
Fax: +98 21 22567282
E-mail: h_sasan@hotmail.com

INTRODUCTION

Although intravesical chemotherapy postpones the recurrence of transitional cell carcinoma (TCC), receiving it by the patients with a single low-risk tumor is a matter of debate.[1] Multiple noncomparative studies have demonstrated the favorable outcomes of the immediate treatment by instillation of mitomycin C after transurethral resection of bladder tumor (TURBT) in cases of TCC.[1-4] We conducted this placebo-controlled, triple-blind, randomized controlled trial to evaluate the effect of immediate mitomycin C instillation following TURBT on early recurrence rate of TCC.

MATERIALS AND METHODS

Between December 2003 and December 2005, we conducted a placebo-controlled, triple-blind, randomized clinical trial in Shohada-

e-Tajrish hospital. We enrolled 56 patients with superficial transitional cell carcinoma. The study was approved by the ethical committee of the Urology and Nephrology Research Center, affiliated to Shaheed Beheshti University of Medical Sciences. Written informed contest was obtained from all patients. Patients with primary or papillary tumors, single tumors of 3 cm or less in size, and low-grade superficial tumors (Ta G1, Ta G2, and T1 G1) were included. Individuals with muscle-invasive or grade 3 tumors or in situ bladder carcinoma on the pathological examination, nontransitional cell carcinoma, invasion to the prostate and the upper urinary tract, and a history of previous TURBT or intravesical chemotherapy were excluded. Using balanced randomization method, we randomly assigned the patients into 2 groups[5]; group 1, with 22 patients who received a single dose of mitomycin C, 30 mg, diluted in 30 mL of distilled water[3] and group 2, with 21 patients who received placebo (distilled water) and were served as controls. After emptying the bladder, mitomycin C and the placebo were instilled intravesically 6 to 24 hours after TURBT. The instillation was retained for 2 hours by catheter clamping and then the bladder was irrigated using normal saline.[6] Side effects of mitomycin C such as cystitis, allergic reactions, hematuria, fever, erythema, skin rash, incontinence, chills, nausea and vomiting, fatigue, weakness, and muscle pain were recorded. The two groups were compared using urinary cytology and cystoscopy at 3, 6, 9, 12, 18, and 24 postoperative months. The time of the onset, location, size, stage, and grade of the recurrent tumors were determined. We compared the two groups by chi-square test and unpaired *t* test. Disease-free interval was calculated using Kaplan-Meier method and the distribution was compared by Breslow test. Values were considered statistically significant at $P < .05$.

RESULTS

One patient with in situ carcinoma and 2 with a high-grade tumor (G3) were excluded from group 1. Also, 3 patients in this group did not complete the study. In group 2, there were 2 patients with high-grade tumor, 2 with muscle invasion (stage T2), and 3 with incomplete follow-up who were excluded. A total of 22 patients in group 1 (subjects) and 21 in group 2 (controls) were evaluated. Table 1 demonstrates the patients' demographic and clinical characteristics. Table 2 shows the recurrence and tumor progression

Table 1. Patients' Demographic and Clinical Characteristics*

Characteristics	Group 1 Mitomycin C	Group 2 Placebo	All	*P*
Number of patients	22	21	43	…
Mean age, y (range)	55.9 ± 13.3 (35 to 82)	53.6 ± 17.9 (22 to 83)	54.8 ± 15.6 (22 to 83)	.6
Male/female	17/5	17/4	34/9	.7
Mean tumor size, cm (range)	1.80 ± 0.77 (0.5 to 3)	1.90 ± 0.80 (0.5 to 3)	1.89 ± 0.80 (0.5 to 3)	.94
Pathological stage*				
pTa	16 (72.7)	15 (71.4)	31 (72.1)	.92
pT1	6 (27.7)	6 (28.6)	12 (54.4)	.92
G1	20 (90.9)	19 (90.5)	39 (90.7)	.96
G2	2 (9.1)	2 (9.5)	4 (9.3)	.96
Mean follow-up, mo (range)	16.7 (9 to 24)	14.7 (9 to 24)	15.7 (9 to 24)	.2

*Values in parentheses are percents unless otherwise indicated.

Table 2. Recurrence and Progression*

Recurrence and Progression	Group 1	Group 2	*P*
Time of Recurrence			
3	0	5 (23.8)	.02
6	0	6 (28.5)	.007
9	1 (4.5)	7 (33.3)	.02
12	1 (4.5)	8 (38.1)	.007
18	1 (4.5)	8 (38.1)	.007
24	1 (4.5)	8 (38.1)	.007
Progression	0	3 (14.3)	.06

*Values in parentheses are percents.

rates in the two groups. Recurrence within the first 3 months was not reported in the patients of group 1, while in group 2, there were 5 patients who experienced recurrence. Of these, 4 had recurrence of tumor in the primary site. In addition, in group 1, only 1 patient (4.5%) had recurrence during the first 12 months compared to 8 (38.1%) in group 2 ($P = .007$).

Table 3 shows the clinical and pathological variables in the patients with recurrence in both groups. We had no patients with multifocal recurrence in group 1, but 3 (14.2%) in group 2. Nine-month tumor-free survival rate was 95% in group 1. Three-, 6-, 9-, and 12-month tumor-free survival rates in group 2 were 76%, 71%, 66%, and 62%, respectively. Survival analysis using Breslow test showed a significant difference between the two groups ($P = .007$). No patient in group 1 and 3 in group 2 (14.3%) experienced some degrees of tumor progression ($P = .06$). The patients in group 1 had a significantly longer recurrence-free interval in comparison with those in group 2. Figure shows comparison of the two groups regarding the recurrence-free survival analysis and Table 4 shows the side effects of mitomycin C versus placebo in the two groups.

Table 3. Clinical and Pathological Characteristics of Recurrence Cases Within 1 Year*

Characteristics	Group 1	Group 2
Number of patients	1	8
Number of the multiple tumors	1 (4.5)	3 (14.2)
Pathological stage		
pTa	1 (4.5)	4 (19.0)
pT1	0	4 (19.0)
pT2	0	0
G1	0	7 (33.3)
G2	1 (4.5)	1 (4.7)
G3	0	0

*Values in parentheses are percents.

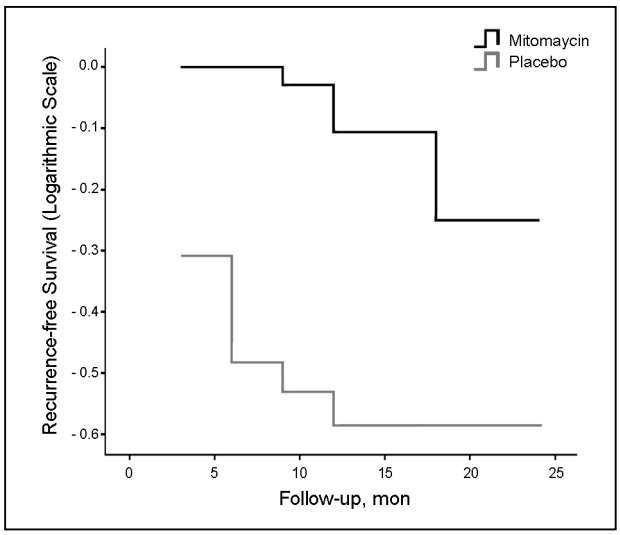

Comparison of the two groups regarding tumor recurrence-free survival.

Table 4. Side Effects of Mitomycin C*

Side Effects	Group 1
Local bladder symptoms	
Dysuria	2 (9.0)
Frequency	1 (4.5)
Pain/cramps/urgency	2 (9.0)
Bacterial cystitis	4 (18.1)
Hematuria	4 (18.1)
Systemic symptoms	
Myalgia	1 (4.5)
Fever and chills	1 (4.5)
Nausea and vomiting	1 (4.5)
Total	10 (45.5)

*None of the side effects were seen in the control group. Values in parentheses are percents.

DISCUSSION

To date, multiple clinical trials have focused on the efficacy of single immediate instillation of chemotherapeutic agents for the treatment of bladder TCC after TURBT. Some studies have been conducted to evaluate the effect of thiotepa, adriamycin, epodyl, and epirubicin.[7-10] Although they provided new evidence of chemotherapy after TURBT, none of the trials were a randomized study.

Zincke and colleagues showed the advantage of thiotepa and doxorubicin instillation at the time of transurethral surgery of bladder cancer.[11] Although their report had an acceptable randomized double-blind design, patients with carcinoma in situ were also enrolled and some patients received additional instillations before the recurrence. A disadvantage of this study was the administration of 2 agents in one arm. In 1985, a study on 417 patients with newly diagnosed superficial bladder tumors (Ta/T1) compared the instillation of thiotepa at the time of primary treatment and its instillation with a 3-month interval. This study showed that neither of these regimens produced sufficient improvement.[12] Thereafter, trials on other chemotherapeutics were reported. Oosterlinck and associates, in a randomized multicenter trial on 431 patients with primary or recurrent Ta or T1 stages of the bladder

tumor, demonstrated that immediate instillation of epirubicin after tumor resection decreased the recurrence rate up to 53%.[13] The main disadvantage of their trial was enrollment of the cases with recurrent tumors. In addition, the control group received water instead of the placebo. In our study, we had no recurrence in our study group. In group 2, 4 out of 5 patients with recurrence within 3 months after the intervention had their tumors in the primary site. This finding provides a support for the hypothesis of Oosterlinck and colleagues who suggested that the recurrences in the original location might be due to tumor cell implantation.

Other studies on epirubicin were surprising. Ali-el-Dein and colleagues performed a randomized controlled trial on 168 patients and showed that immediate instillation of a single-dose epirubicin is as effective as delayed maintenance therapy (epirubicin 1 to 2 weeks after TURBT, 8 weeks later, and monthly up to 1 year, thereafter).[14]

In a randomized control trial on 131 patients with superficial bladder cancer, Solsona and coworkers found a positive effect of a single immediate mitomycin C instillation.[3] They did not use placebo in their control group and enrolled cases with recurrent tumors in their study. In our study, we observed only 1 patient (4.5%) with recurrence during the first 12 months compared to 8 (38.1%) in the control group. Therefore, follow-up cystoscopies at 3, 6, and 9 postoperative months could have been limited and substituted with noninvasive procedures like ultrasonography and cytology in cases who received mitomycin C. Tolley and colleagues carried out a multicenter randomized control trial on 452 patients with newly diagnosed superficial bladder cancer and showed the positive but nonsignificant benefits of mitomycin C.[4] Although this study included a large number of cases, they enrolled patients at low, medium, and high risk for the subsequent recurrences.

Some researchers conducted other studies for evaluating the effects of other chemotherapeutics. Two clinical trials showed the positive effects of epirubicin and doxorubicin.[15,16] Rajala and colleagues[15] showed a sustained decrease in the recurrence of bladder cancer after a single perioperative instillation of epirubicin and ineffectiveness of interferon-α for this purpose. For patients in the control group, transurethral resection alone was performed and the cases with grades 1 to 3 of the bladder cancer were included. Okamura and associates performed a randomized study comparing 6 and 17 instillations of doxorubicin in patients with single superficial bladder cancer.[16] Subjects with new or recurrent tumors were enrolled in that study. In our study, we had no patients with multifocal recurrence in the subjects group but 3 (14.2%) in the controls. This finding shows that mitomycin C may decrease the transition from low-risk state to high-risk condition and alleviate the necessity of the therapy with bacillus Calmette-Guerin.

The main disadvantages of all the abovementioned studies were no administration of placebo in the control groups and enrollment of the cases with recurrent tumors that might enter some confounding variables in the study due to the effects of the previous treatment modalities. To our best knowledge, all of the mentioned clinical trials provided a high level of evidence demonstrating the benefit of immediate instillation of mitomycin C after TURBT. Using placebo in our protocol and a method of balanced randomization protect our findings from potential confounders. Since we enrolled cases with newly diagnosed primary bladder tumors of stage Ta/T1 in protocol, our findings seem to be free of effects resulting from previous treatment modalities.

We acknowledge the limited number of patients in our study and a relatively high proportion of excluded cases. However, according to our results and previous evidence mentioned above, immediate instillation of mitomycin C within 6 to 24 hours following TURBT seems to be effective and decreases the short-term recurrence rate while prolongs recurrence-free interval. In addition, as our study and previous reports showed, this treatment provides prevention from tumor progression.
A new protocol introduced by 2 pioneers, Nieder and Soloway, demonstrated that after the diagnosis of low-grade bladder tumors (Ta/T1), treatment schedule should include TURBT and mitomycin C. They recommend therapy by bacillus Calmette-Guerin be added to this protocol for high-grade tumors.[17]

CONCLUSION

Our results demonstrate the superiority of mitomycin C versus placebo in the prophylaxis of the recurrence in primary low-risk superficial bladder TCC following TURBT. Consequently, we strongly recommend instillation of mitomycin C in the first 24 hours after the tumor resection.

CONFLICT OF INTEREST

Drs Seyed Mohammad Mehdi Hosseini Moghaddam and Mehrnoosh Jahanbin are the full-time researchers of the Urology and Nephrology Research Center, the sponsor of the study.

FUNDING SUPPORT

This study was financially supported by the Urology and Nephrology Research Center affiliated with Shaheed Beheshti University of Medical Sciences.

REFERENCES

1. Sylvester RJ, Oosterlinck W, van der Meijden AP. A single immediate postoperative instillation of chemotherapy decreases the risk of recurrence in patients with stage Ta T1 bladder cancer: a meta-analysis of published results of randomized clinical trials. J Urol. 2004;171:2186-90.
2. Bohle A, Jocham D, Bock PR. Intravesical bacillus Calmette-Guerin versus mitomycin C for superficial bladder cancer: a formal meta-analysis of comparative studies on recurrence and toxicity. J Urol. 2003;169: 90-5.
3. Solsona E, Iborra I, Ricos JV, Monros JL, Casanova J, Dumont R. Effectiveness of a single immediate mitomycin C instillation in patients with low risk superficial bladder cancer: short and long-term follow up. J Urol. 1999;161:1120-3.
4. Tolley DA, Parmar MK, Grigor KM, et al. The effect of intravesical mitomycin C on recurrence of newly diagnosed superficial bladder cancer: a further report with 7 years of follow up. Urol. 1996;155:1233-8.
5. Peto R, Pike MC, Armitage P, et al. Design and analysis of randomized clinical trials requiring prolonged observation of each patient. I. Introduction and design. Br J Cancer. 1976;34:585-612.
6. Au JL, Badalament RA, Wientjes MG, et al. International Mitomycin C Consortium. Methods to improve efficacy of intravesical mitomycin C: results of a randomized phase III trial. J Natl Cancer Inst. 2001;93:597-604.
7. Burnand KG, Boyd PJ, Mayo ME, Shuttleworth KE, Lloyd-Davies RW. Single dose intravesical thiotepa as an adjuvant to cystodiathermy in the treatment of transitional cell bladder carcinoma. Br J Urol. 1976;48: 55-9.
8. Abrams PH, Choa RG, Gaches CG, Ashken MH, Green NA. A controlled trial of single dose intravesical adriamycin in superficial bladder tumours. Br J Urol. 1981;53:585-7.
9. Kurth KH , Maksimovic PA , Hop WCJ , Schröder FH, Bakker NJ. Single-dose intravesical Epodyl after TUR of Ta TCC bladder carcinoma. World J Urol. 1983;1: 89-93.
10. Selvaggi FP, de Micheli P, Pamparana F, Sacchetti G. Epirubicina endovesicale nella profilassi delle recidive dei tumori superficiali della vesica. Studio multicentrico, randomizzato. Acta Urol Ital. 1990;1:331.
11. Zincke H, Utz DC, Taylor WF, Myers RP, Leary FJ. Influence of thiotepa and doxorubicin instillation at time of transurethral surgical treatment of bladder cancer on tumor recurrence: a prospective, randomized, double-blind, controlled trial. J Urol. 1983;129:505-9.
12. [No authors listed]. The effect of intravesical thiotepa on the recurrence rate of newly diagnosed superficial bladder cancer. An MRC Study. MRC Working Party on Urological Cancer. Br J Urol. 1985;57:680-5.
13. Oosterlinck W, Kurth KH, Schroder F, Bultinck J, Hammond B, Sylvester R. A prospective European Organization for Research and Treatment of Cancer Genitourinary Group randomized trial comparing transurethral resection followed by a single intravesical instillation of epirubicin or water in single stage Ta, T1 papillary carcinoma of the bladder. J Urol. 1993;149: 749-52.
14. Ali-el-Dein B, Nabeeh A, el-Baz M, Shamaa S, Ashamallah A. Single-dose versus multiple instillations of epirubicin as prophylaxis for recurrence after transurethral resection of pTa and pT1 transitional-cell bladder tumours: a prospective, randomized controlled study. Br J Urol. 1997;79:731-5.
15. Rajala P, Kaasinen E, Raitanen M, Liukkonen T, Rintala E; Finnbladder Group. Perioperative single dose instillation of epirubicin or interferon-alpha after transurethral resection for the prophylaxis of primary superficial bladder cancer recurrence: a prospective randomized multicenter study--FinnBladder III long-term results. Urol. 2002;168:981-5.
16. Okamura K, Ono Y, Kinukawa T, et al. Randomized study of single early instillation of (2”R)-4’-O-tetrahydropyranyl-doxorubicin for a single superficial bladder carcinoma. Cancer. 2002;94:2363-8.
17. Nieder AM, Soloway MS. Eliminate the term “superficial” bladder cancer. J Urol. 2006;175:417-8.