

Vanishing Shaft of a Double-J Stent

Rahul Gupta, Pranjal Modi, Jamal Rizvi

Keywords: indwelling catheters, foreign bodies, stents, iatrogenic disease

Urol J. 2008;5:277-9.
www.uj.unrc.ir

INTRODUCTION

“Forgotten” indwelling stents can result in complications such as encrustation, pyelonephritis, recurrent obstruction, and stent migration and breakage.^(1,2)

We report a case of forgotten stent with encrustation of the proximal and distal ends, spontaneous disappearance of the middle segment, and an associated *hourglass* pelvic stenosis resulting in hydronephrosis.

Institute of Kidney Diseases and Research Centre, Ahmedabad, Gujarat, India

Corresponding Author:
Rahul Gupta, MD

Institute of Kidney Diseases and Research Centre, Ahmedabad, Gujarat, India

Tel: +91 942 760 9778

E-mail: rajaguptadr@rediffmail.com

CASE REPORT

A 56-year-old man presented with the history of frequency, urgency, and dysuria for 2 months. He had undergone right open pyelolithotomy 10 years earlier. On evaluation, serum urea and creatinine values were within normal limits. Urinalysis revealed microscopic pyuria and hematuria. Urine culture was positive for *Escherichia coli*. Ultrasonography of the kidney revealed a normal left kidney, but

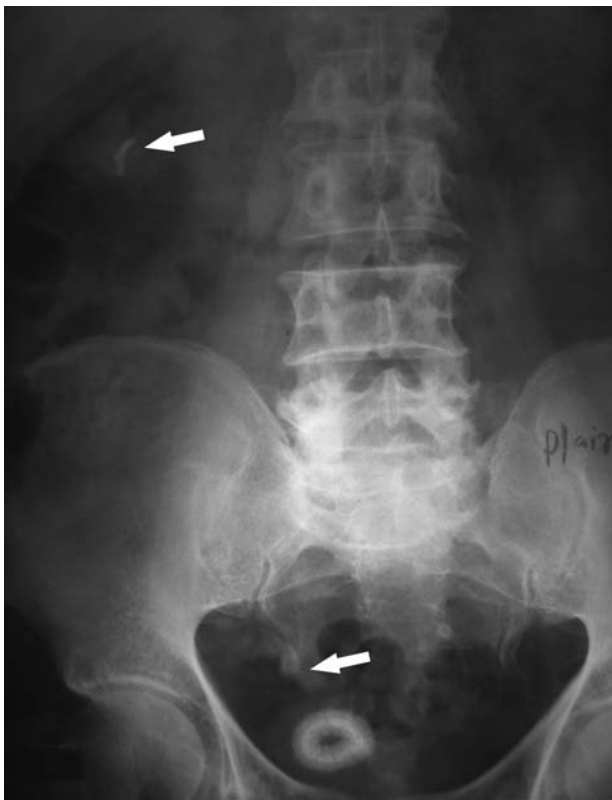

Figure 1. Plain abdominal radiography shows coiled double J stent in the kidney and bladder region with encrustation (arrows).

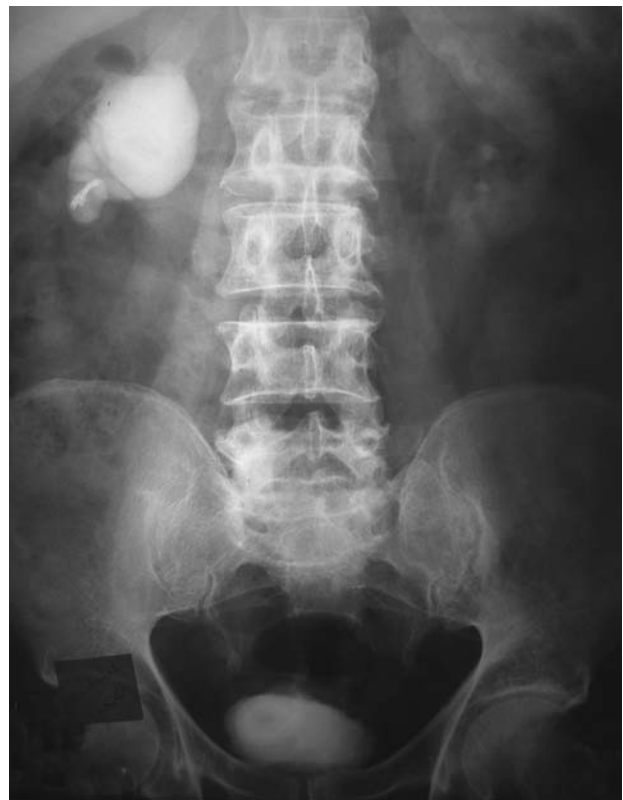

Figure 2. Intravenous urography shows good function of the right kidney.

moderate hydronephrosis with a lower calyceal calculus (1 × 1 cm) in the right kidney. Bladder ultrasonography revealed a calculus, as well.

Plain abdominal radiography revealed coiled ends of a polyurethane double-J stent in the right kidney and bladder region with encrustation; however, the entire shaft of the stent was missing (Figure 1). Intravenous urography revealed normal left renal unit, but in the right side, delayed excretion of the contrast medium and presence of moderate hydronephrosis was seen. No contrast medium was noted beyond the ureteropelvic junction (Figure 2).

The patient was treated by antibiotics according to the microbial sensitivity test results. Cystolithotripsy and right percutaneous nephrostomy were then performed. Antegrade and retrograde imaging study were suggestive of *hourglass* pelvic stenosis (Figure 3). The patient was subjected to right percutaneous nephrolithotomy followed by transperitoneal laparoscopic pyelopyeloplasty (Figure 4). His postoperative recovery was uneventful.

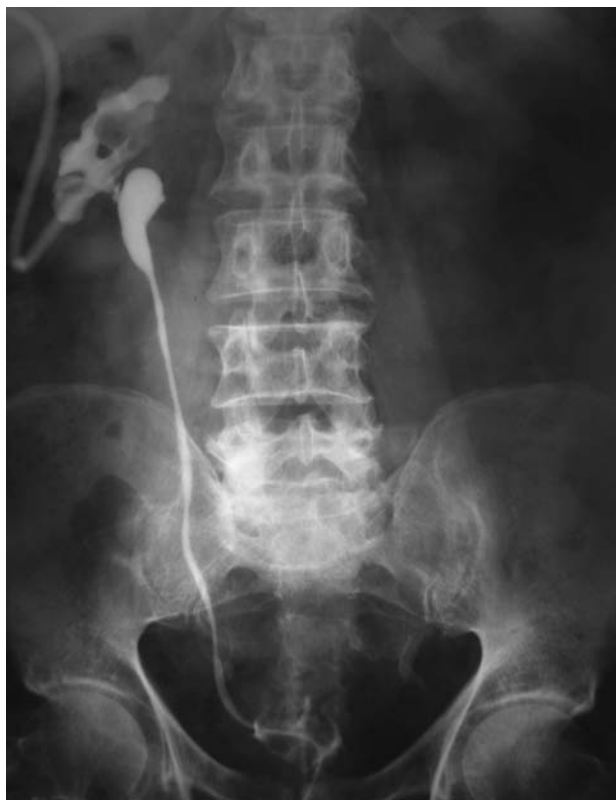

Figure 3. Bidirectional contrast study reveals pelvic stenosis.

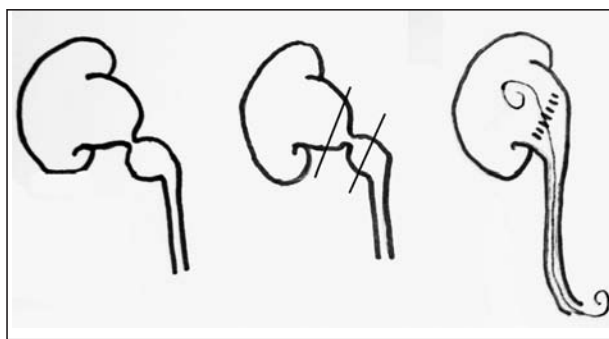


Figure 4. **Left**, Line diagram demonstrates the hourglass-shaped pelvic stricture. **Middle**, Excision of the stricture segment. **Right**, Final appearance after pyelopyeloplasty using 5-0 vicryl suture.

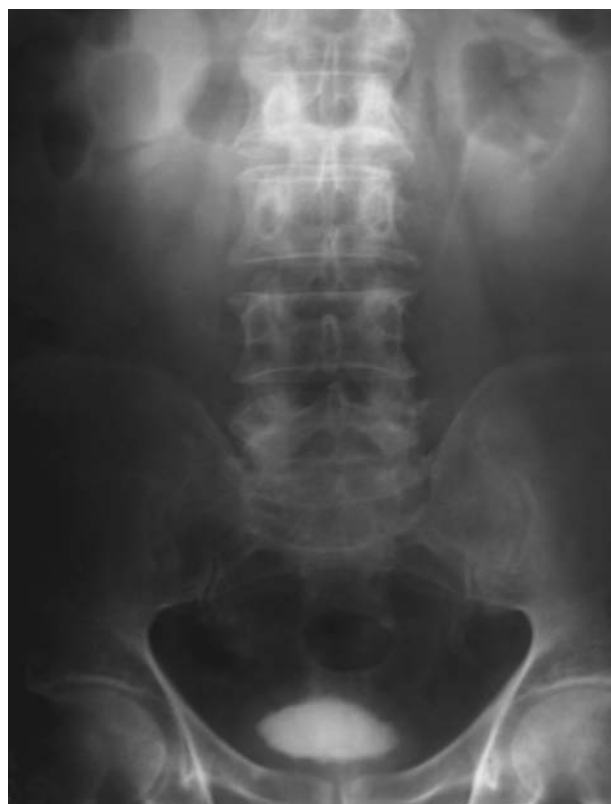

Figure 5. Follow-up intravenous urography shows good function and drainage of the right kidney.

Nephrostography on the 7th postoperative day showed prompt drainage with no evidence of extravasation. Intravenous urography at the 6th week revealed prompt drainage of the contrast medium (Figure 5).

DISCUSSION

Various problems with indwelling stents have been reported, one of the most prevalent of which is “forgotten stents.”^(1,2) The rate of encrustation

is significantly related to the duration of stenting or dwelling time. El-Faqih and colleagues noted a 9.6% encrustation rate for stents of less than 6 weeks duration, which increased to 47.5% for those of 6 to 12 weeks and 76.3% for those of more than 12 weeks of duration; therefore, they recommended early removal of the stents.⁽¹⁾ Patients with encrusted long-standing stents may require endourological procedures, extracorporeal shock wave lithotripsy, or laparoscopy for the removal of their stents.⁽³⁻⁵⁾

Spontaneous and procedure-induced stent fragmentation have been reported.^(6,7) Kumar and colleagues showed stent fragmentation into multiple pieces over a mean indwelling time of 3.5 months.⁽⁸⁾ Our patient had a retained stent for 10 years. The distal and proximal coils of the stent were encrusted, probably due to the prolonged period of contact with urine in the bladder and renal pelvic stenosis leading to urine stasis, respectively. We believe that due to encrustation, both ends of the stent were retained in situ and the central shaft was degraded and vanished.

In addition, the bidirectional contrast study revealed an hourglass pelvic stricture, which would have resulted from the previous open pyelolithotomy and aggravated by the inflammatory reaction caused by encrusted retained stent fragment. Laparoscopic pyeloplasty has been effective for secondary ureteropelvic junction obstruction.⁽⁹⁾ Instead of conventional pyeloplasty, we opted for pyelopyeloplasty because of good vascularity of both cut ends of the pelvis and good patency of the ureteropelvic junction. In order to prevent leakage of the urine in early postoperative days, antegrade stenting was performed intra-operatively. The stent was removed after 3 weeks.

In conclusion, hourglass deformity of the renal pelvis is rare and retention of both ends of the stents and its vanishing shaft is uncommon. Combined endourological and laparoscopic approach is a good alternative to manage such cases without morbidity. To our knowledge, this is the first case report of laparoscopic pyelopyeloplasty for hourglass deformity of the renal pelvis.

CONFLICT OF INTEREST

None declared.

REFERENCES

1. El-Faqih SR, Shamsuddin AB, Chakrabarti A, et al. Polyurethane internal ureteral stents in treatment of stone patients: morbidity related to indwelling times. *J Urol.* 1991;146:1487-91.
2. Monga M, Klein E, Castaneda-Zuniga WR, Thomas R. The forgotten indwelling ureteral stent: a urological dilemma. *J Urol.* 1995;153:1817-9.
3. Aravantinos E, Gravas S, Karatzas AD, Tzortzis V, Melekos M. Forgotten, encrusted ureteral stents: a challenging problem with an endourologic solution. *J Endourol.* 2006;20:1045-9.
4. Lam JS, Gupta M. Tips and tricks for the management of retained ureteral stents. *J Endourol.* 2002;16:733-41.
5. Bhansali M, Patankar S, Dobhada S. Laparoscopic management of a retained heavily encrusted ureteral stent. *Int J Urol.* 2006;13:1141-3.
6. Adsan O, Guner E, Ozturk B, Ataman T, Cetinkaya M. Spontaneous fragmentation of a double J stent. *Int Urol Nephrol.* 1997;29:307-11.
7. Ilker Y, Turkeri L, Dillioglugil O, Akdas A. Spontaneous fracture of indwelling ureteral stents in patients treated with extracorporeal shock wave lithotripsy: two case reports. *Int Urol Nephrol.* 1996;28:15-9.
8. Kumar M, Aron M, Agarwal AK, Gupta NP. Stenturia: An unusual manifestation of spontaneous ureteral stent fragmentation. *Urol Int.* 1999;62:114-6.
9. Levin BM, Herrell SD. Salvage laparoscopic pyeloplasty in the worst case scenario: after both failed open repair and endoscopic salvage. *J Endourol.* 2006;20:808-12.