

Stenturia

A Rare Complication of Indwelling Ureteral Stent

Vishwajeet Singh, Ankush Gupta

Keywords: stents, ureter, postoperative complications

Urol J. 2009;6:226-7.
www.uj.unrc.ir

INTRODUCTION

It is now more than 30 years that ureteral stents have been used for the management of urinary calculi. With its widespread use, the number of possible complications has increased, as well. Over the years, ureteral stents have undergone a progressive improvisation, both in design and material. In the current era, the side effect profile of double-J stents has improved. Common complications have been lower abdominal pain, dysuria, hematuria, fever, urinary frequency, and nocturia.^(1,2) however, there is still no place for forgotten stents. Long-term indwelling ureteral stents have led to stent migration, encrustation, calculus formation, and spontaneous fragmentation.⁽³⁾ Spontaneous fragmentation and excretion of fragments in urine is extremely rare. Herein, we report a case of forgotten ureteral stent presented to our center.

CASE REPORT

A 35-year-old man presented with right flank pain lasted for 6 months. There were no other associated symptoms. Ultrasonography of the kidneys, ureters, and bladder showed multiple calculi with hydronephrosis in the right kidney and multiple left inferior caliceal calculi. The renal

laboratory indicators were normal. Intravenous urography revealed hydronephrosis in the right kidney with a calculus at the ureteropelvic junction and multiple left inferior caliceal calculi, with good dye excretion on both sides.

Initially, the patient was managed by insertion of a right double-J stent. He was advised to undergo right percutaneous nephrolithotomy. However, the patient was then lost to follow-up. After 1 year, he returned with a piece of approximately 5-cm tubular foreign body right after the initial part of the urethra (Figure 1). This was a piece of previously inserted double-J stent. The patient was also complaining from hematuria. Since the patient had been lost to follow-up, urinary tract infections could not be documented. Although careful history was taken at the time of the second presentation to elucidate previous urinary tract infections, it was not suggestive of recurrent infections. Plain abdominal radiography showed fragmented pieces of the stent in the urinary bladder and the right pyelocaliceal system (Figure 2). The fragment in the bladder was retrieved by cystoscopy, and 1 week later, the proximal fragment in the pyelocaliceal system and the calculus were extracted by percutaneous nephrolithotomy.

Department of Urology, Chhatrapati
Shahuji Maharaj Medical University,
Lucknow, Uttar Pradesh, India

Corresponding Author:
Ankush Gupta, MD

Department of Urology, Chhatrapati
Shahuji Maharaj Medical University,
Lucknow 226003, Uttar Pradesh,
India

Tel: +91 52 2225 6543

Fax: +91 52 2225 6543

E-mail:ankushuro@gmail.com

Received May 2008

Accepted July 2008




Figure 1. An approximately 5-cm long piece of stent passed through the urethra.

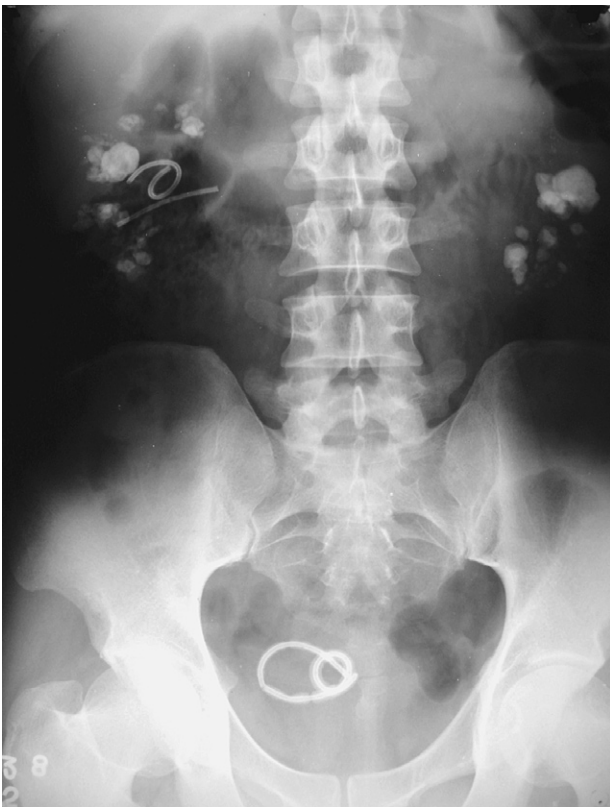

Figure 2. Plain abdominal radiography of the patient showed fragmented pieces of the stent in the bladder and the right pyelocaliceal system.

DISCUSSION

Late complications of ureteral stents occur in about one-third of the patients.⁽⁴⁾ El-Faqih and colleagues reported a spontaneous fragmentation rate of 0.3% in a review of complications associated with the presence of ureteral stents.⁽⁵⁾ Stent breakage is thought to be due to the

hostility of the urine solution and prolonged indwelling time (more than 1 year). All ureteral stents may develop encrustation and lose tensile strength which results in stent fracture and even stenturia.⁽⁶⁾ Lithogenic factors need to be considered for the prevention of stent encrustation in these patients.⁽⁷⁾ The clinical presentations may vary. Three previous cases of this kind have been reported in the literature whose stent fragment was spontaneously excreted.^(8,9) However, management of neglected or complicated forgotten ureteral stents usually needs endourological approaches.⁽¹⁰⁾ This underscores the need for close follow-up of patients with in situ stents.

CONFLICT OF INTEREST

None declared.

REFERENCES

1. Pollard SG, Macfarlane R. Symptoms arising from Double-J ureteral stents. *J Urol.* 1988;139:37-8.
2. Damiano R, Oliva A, Esposito C, De Sio M, Autorino R, D'Armiento M. Early and late complications of double pigtail ureteral stent. *Urol Int.* 2002;69:136-40.
3. Monga M, Klein E, Castañeda-Zúñiga WR, Thomas R. The forgotten indwelling ureteral stent: a urological dilemma. *J Urol.* 1995;153:1817-9.
4. Ringel A, Richter S, Shalev M, Nissenkorn I. Late complications of ureteral stents. *Eur Urol.* 2000;38:41-4.
5. El-Faqih SR, Shamsuddin AB, Chakrabarti A, et al. Polyurethane internal ureteral stents in treatment of stone patients: morbidity related to indwelling times. *J Urol.* 1991;146:1487-91.
6. Singh I. Indwelling JJ ureteral stents-A current perspective and review of literature. *Indian J Surg.* 2003;65:405-12.
7. Bouzidi H, Traxer O, Dore B, et al. [Characteristics of encrustation of ureteric stents in patients with urinary stones]. *Prog Urol.* 2008;18:230-7. French.
8. Kumar M, Aron M, Agarwal AK, Gupta NP. Stenturia: An unusual manifestation of spontaneous ureteral stent fragmentation. *Urol Int.* 1999;62:114-6.
9. Soyupek S, Oksay T, Koşar A. Fragmentation of a forgotten double J stent and excreted with urine: case report. *Int Urol Nephrol.* 2003;35:91-2.
10. Singh V, Srinivastava A, Kapoor R, Kumar A. Can the complicated forgotten indwelling ureteric stents be lethal? *Int Urol Nephrol.* 2005;37:541-6.